

CASE REPORT

A Case of Peripheral Ossifying Fibroma with Review of Literature

¹Rohit Agrawal, ²Shipra Agrawal, ³Rahul Agrawal

ABSTRACT

Peripheral ossifying fibroma (POF) is an enlargement of the gingiva with randomly distributed calcifications, immature bone, and osteoid and is nonneoplastic in nature. It is found only on the gingiva. Clinically, it resembles a peripheral fibroma, but histopathologic analysis always reveals immature bone and osteoid within the lesion. Peripheral ossifying fibroma exhibits histomorphological features similar to ossifying fibroma. Some reports suggest that both originate from periodontal ligament (PDL) cells. However, POF is not considered to be a neoplastic lesion but a hyperplastic reaction caused by chronic inflammation. We report a case of POF present in the mandibular anterior region in a middle-aged female patient. Clinical, radiographic, and histopathological features along with etiopathogenesis and differential diagnosis are also discussed.

Keywords: Hyperplastic reaction, Ossifying fibroma, Peripheral fibroma, Peripheral ossifying fibroma.

How to cite this article: Agrawal R, Agrawal S, Agrawal R. A Case of Peripheral Ossifying Fibroma with Review of Literature. *Int J Prev Clin Dent Res* 2016;3(3):216-220.

Source of support: Nil

Conflict of interest: None

INTRODUCTION

There are two types of ossifying fibroma: Central and peripheral. The central variety originates from the endosteum or periodontal ligament (PDL) near the root apex and then expands from the medullary cavity of the bone in the outward direction. The peripheral variety occurs exclusively on the soft tissue overlying the alveolar process and is a "nonneoplastic," reactive fibrous proliferation of gingival although some authors consider it to be neoplastic.¹⁻⁸

Peripheral ossifying fibroma (POF) is an intraoral lesion found solely on the gingiva and not in any other oral mucosal location.⁹ Its color varies from pale pink to cherry red and is either pedunculated or sessile,⁴ and interdental papilla area is its common location.⁹ The lesion may cause drifting of the adjacent teeth, and rarely minimal bone resorption can be seen beneath the lesion.^{2,10,11} It is found most frequently in teenagers and young adults. Women are 2 to 4 times more commonly affected than men between the age group of 25 to 35 years.^{4,6,12,13} It is a separate entity and not a soft tissue counterpart of central ossifying fibroma.^{2,6}

CASE REPORT

A 45-year-old female presented with a growth in the lower front teeth region since 4 months (Fig. 1). Initially, the exophytic growth was small peanut sized but it slowly progressed to current size. Initially, the lesion was asymptomatic but now it has increased in its size. Patient also complained of pain while chewing food, due to impingement of maxillary anterior teeth on the growth. The patient had consulted several local doctors in the past and took medications but the lesion did not subside.

A solitary pedunculated well-defined exophytic lesion was present on the interdental gingiva in the region of 32 and 33. It was oval in shape measuring 2 cm in its greatest dimension, pale in color. There was erosion present with a coating of slough as a secondary change on its superior surface.

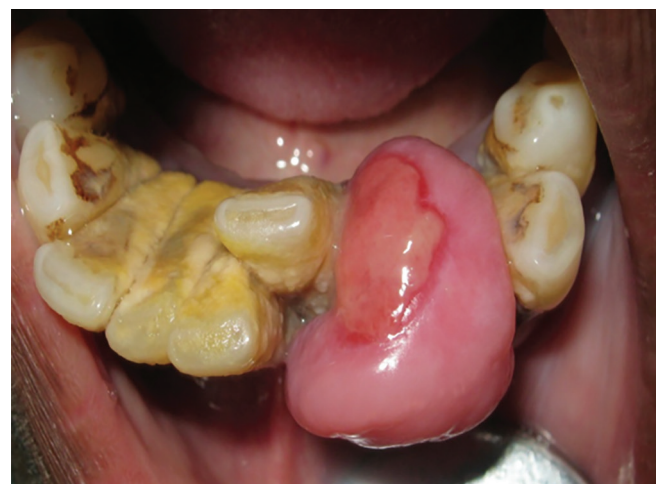

Fig. 1: Intraoral picture of the lesion

¹Reader, ²Senior Lecturer, ³Head

¹Department of Oral Medicine and Radiology, Maharana Pratap College of Dentistry and Research Centre, Gwalior, Madhya Pradesh, India

²Department of Conservative Dentistry and Endodontics Maharana Pratap College of Dentistry and Research Centre Gwalior, Madhya Pradesh, India

³Department of ENT, Agrawal Hospital and Research Institute Gwalior, Madhya Pradesh, India

Corresponding Author: Rohit Agrawal, Reader, Department of Oral Medicine and Radiology, Maharana Pratap College of Dentistry and Research Centre, Gwalior, Madhya Pradesh, India Phone: +919425101830, e-mail: rhtagrawal83@gmail.com rohmaha@yahoo.co.in

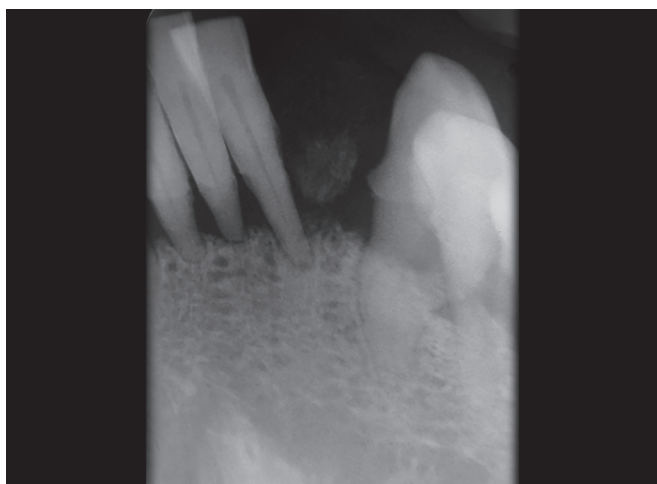


Fig. 2: Intraoral periapical radiograph showing diffused radiopaque foci

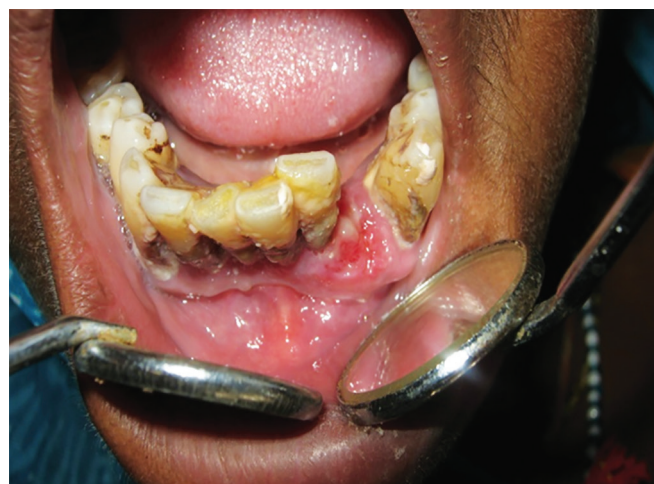

Fig. 3: Postoperative picture

On palpation, it was slightly tender on the superior aspect where there was erosion while in rest of the areas it was nontender. It was firm in consistency, mobile, non-compressible, nonreducible, and nonpulsatile. Moreover, 31 and 32 were mesially drifted while 41 was distally drifted due to the growth. A provisional diagnosis of fibroma was given. The differential diagnosis included peripheral giant cell granuloma (PGCG), irritational fibroma, pyogenic granuloma, POF, and metastatic cancer.

Vitality test was done for all the mandibular teeth with electric pulp tester which elicit negative response with 31, 32, 41, and 42.

An intraoral periapical (IOPA) radiograph was taken of the region of 31, 32, 33, and 41. Radiograph showed diffused irregular-shaped radiopacity present in the interdental area of 32 and 33 with the background of a radiolucent area (Fig. 2).

Institution's ethical committee had given the ethical clearance. The patient was explained thoroughly about the whole surgical procedure being used and its related risks and benefits, after which her consent was taken. Excisional biopsy was done under local anesthesia (Fig. 3), followed by ultrasonic scaling of the adjacent teeth and the patient was recalled after 7 days of follow-up. Histopathological examination of the excised specimen revealed hyperplastic stratified squamous epithelium and at foci discontinuous atrophic epithelium. The underlying connective tissue shows presence of ossification and numerous small-sized blood vessels along with dense inflammatory cell infiltrate, which confirmed the final diagnosis of POF (Fig. 4). The healing was uneventful with no recurrence at a 1-year follow-up.

DISCUSSION

Described this lesion as peripheral fibroma with calcification and the term POF was coined.^{14,15} Analogous lesions

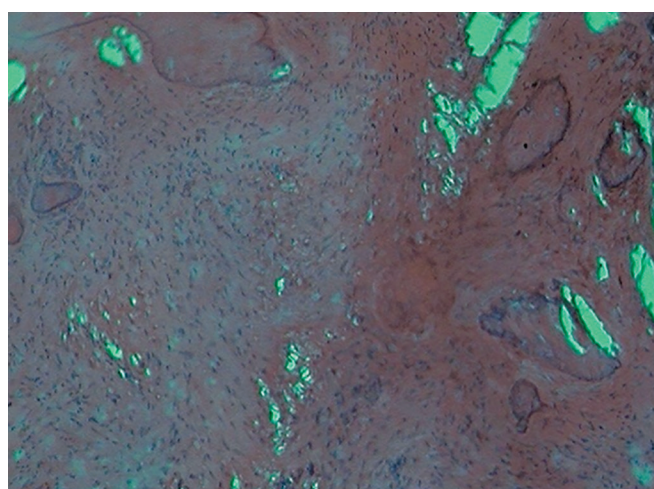


Fig. 4: Histopathological examination showing hyperplastic squamous epithelium with underlying ossification and lymphocytic infiltration (10×, H&E stain)

have been termed with various names, such as calcifying or ossifying fibrous epulis,^{6,16} peripheral fibroma with calcification,⁶ POF,^{4,7} calcifying fibroblastic granuloma,¹⁷ peripheral cementifying fibroma, peripheral fibroma with cementogenesis,¹⁸ peripheral cemento-ossifying fibroma,¹⁹ and ossifying fibroma epithelial polyp.^{20,21} So far, there have been multiple names used for fibroblastic gingival lesions which confirms the fact that there is much controversy regarding the classification of these lesions.^{18,22} The term peripheral odontogenic fibroma has also been used interchangeably with POF but should be avoided as World Health Organization has declared peripheral odontogenic fibroma as the rare extraosseous supplement of central odontogenic fibroma.^{5,7,22}

Ossifying fibroma may show varied presence of bone, cementum, and spheroidal calcifications, that is why so many names have been given for these benign fibro osseous lesions. When bone contributes to major part then the term ossifying applies while the name

cementifying has been denoted when curvilinear trabeculae or spheroidal calcifications predominates in percentage. When bone and cementum-like tissues are observed, the lesions have been the terminology of cemento-ossifying fibroma.²³ Clinically and radiographically, it is almost impossible to separate cementifying fibromas from ossifying fibroma.²⁴

The clinical presentation and histopathology of cemento-ossifying fibroma are the same in the areas, such as skull, femur, and tibia where cementum is absent; therefore the term “cemento-ossifying fibroma” is now considered antiquated.²⁵ Out of all the oral lesions that are biopsied, POF contributes only 2% which signifies its rarity.²⁶

Etiopathogenesis of POF is quite controversial. Local etiological factors, such as subgingival plaque and calculus, trauma, dental appliances, poor-quality dental restorations, microorganism, food lodgment, masticatory forces, cells of periodontal ligament PdL,¹⁸ and iatrogenic factors all influence the development of the lesion.^{4,5,14} The reason why PdL has been considered as one of the etiological factors of POF is because of its solely occurrence in the gingiva (interdental papilla), the closeness of gingiva to the PdL, and the occurrence of oxytalan fibers within the mineralized matrix of few lesions.¹⁸ Some of the researchers have hypothesized that few POF evolve initially as pyogenic granuloma which undergone subsequent calcification, preceded by fibrous maturation because of the similarities between their clinical and histopathological features. However, this process of development does not apply universally to all the POF. The mineralized product probably has its origin from the cells of the PdL ligament. This reactive proliferation is named because of the histologic evidence of calcifications that are seen in the context of a hypercellular fibroblastic stroma. Because of their clinical and histopathologic similarities, researchers believe that some POF develop initially as pyogenic granulomas that undergo fibrous maturation and subsequent calcification.

However, not all POF may develop in this manner.² The mineralized component of POF varies, occurring in approximately 35%²⁷ or 50 to 75%^{6,22,28} of cases according to published reports.

Mineralization can vary between cementum-like material, bone (woven and lamellar), and dystrophic calcification. Most of the oral pathologists consider it to be a type of inflammatory hyperplasia.¹¹ Lesions occurring within the proximity of gingiva are rare, as seen in our case in comparison to the lesions occurring within bone.²⁴ Mesquita et al¹⁴ found higher numbers of Argyrophilic Nucleolar Organizer Regions (AgNORs) and proliferating cell nuclear antigen (PCNA)-positive cells in ossifying

fibroma in comparison to POF, which concluded that ossifying fibroma has higher proliferative activity.

It has been hypothesized that the POF represents a distinct clinical entity rather than a transitional form of pyogenic granuloma, PGCG, or irritation fibroma.⁶ Eversole and Rovin⁴ stated that pyogenic granuloma, PGCG, and POF all have similar sex and site predilection of occurrence intraorally and they also share common clinical and histologic features which lead to the conclusion that they may be simply varied from histologic responses to local provocative factors. Buchner and Hansen²⁸ hypothesized that early POF presents as ulcerated nodules with little calcification leading to be misdiagnosed as a pyogenic granuloma.

The POF is predominantly lesion of teenagers and young adults, with peak prevalence between the ages of 10 and 19, but as in our case, the patient was in her fourth decade of life. Almost two-thirds of all cases occur in females.^{10,27} Hormonal influences may play a role, given the higher number of POF cases seen among females. Its chances of occurrence increase in the 2nd decade and decline after the 3rd decade.²⁷ A total of 80% of the lesions occur anteriorly to molar areas, over 50% occur in the incisor cuspid region and 60% occur in the maxilla.¹¹

Generally, the teeth remain unaffected, but rarely, there can be migration and loosening of adjacent teeth,¹⁰ as in our case where the lesion was present in the mandibular arch which also caused drifting of adjacent teeth.

Peripheral ossifying fibroma may present as a single pedunculated growth, or it can be sessile.^{2,6,9} These lesions vary in color from red to pink with scattered areas of ulceration, having surface that can be either smooth or irregular. They are commonly smaller in size <2 cm in diameter,^{2,28} but its size ranges from 0.2–3.0 cm²⁸ to 4 mm–8 cm,⁶ and rarely according to some reports, few lesions may be as large as 9 cm in diameter.¹⁰ The patient may complain of the presence of lesion for quite long time, ranging from months to even years before he or she got it excised but again it depends on the degree of ulceration, discomfort, and interference with function that it had caused.^{6,28} Rarely, multicentric variety of POF may be present, which can be observed in conditions like nevoid basal cell carcinoma syndrome (multiple odontogenic keratocysts), multiple endocrine neoplasia type II (multiple neuromas), neurofibromatosis (multiple neurofibromas), and Gardner's syndrome (multiple neoplasms).²⁹

Peripheral ossifying fibroma can present with different radiographic features varying from case to case. Calcifications of the lesion that gives a radiopaque picture in the radiograph are mostly concentrated in the central area of the lesion, but radiographically not all

lesions show its presence.^{18,25,29,30} Radiographically, one cannot see the involvement of the underlying bone but rarely one can make out superficial erosion of bone.³⁰ In our case, faint radiographic findings were found in the form of slight amount of radiopaque foci suggestive of dystrophic calcification.

The treatment of choice for the POF is local surgical excision⁶ with aggressive scaling to remove all local etiological factors like bacterial plaque,¹⁸ with submission of excised tissue for histopathologic analysis. The lesion should be completely removed up to the underlying periosteum along with the affected PdL because if any tissue is leftover from the base of the mass then recurrence is likely to occur.^{10,12,25} Although excision is usually curative, recurrence rate of 8 to 20% has been reported; therefore, follow-up is must in such cases.^{2,4,6,28,31} The confirmed diagnosis of POF is made by histopathologic examination of the biopsied tissue sample. The following features are commonly observed under microscopic examination: (1) Benign fibrous connective tissue with varying contents of fibroblasts, myofibroblasts, and collagen; (2) sparse to profuse endothelial proliferation; (3) mineralized material which can be either mature, lamellar, or woven osteoid, cementum-like material or dystrophic calcifications. Sometimes acute or chronic inflammatory cells may also be present.^{3,18} In our patient, the histopathological evaluation of the excised lesion revealed inflammatory infiltrate along with calcification in the underlying connective tissue and hyperplastic epithelium.

CONCLUSION

Peripheral ossifying fibroma is a slowly enlarging lesion, with a limited growth potential. As it clinically resembles pyogenic granuloma, PGCG, or odontogenic tumors, radiographic and histopathological examination is a must to confirm its diagnosis. Treatment consists of local surgical excision including the periosteum and aggressive scaling of adjacent teeth to remove all potential etiological factors. Due to its relatively high recurrence rate up to 20%, a long-term postoperative follow-up is very important in such cases.

REFERENCES

1. Moon WJ, Choi SY, Chung EC, Kwon KH, Chae SW. Peripheral ossifying fibroma in the oral cavity: CT and MR findings. *Dentomaxillofac Radiol* 2007 Mar;36(3):180-182.
2. Neville BW, Damm DD, Allen CM, Bouquot JE. Soft tissue tumors. In: Neville BW, Damm DD, Allen CM, Bouquot JE, editors. *Oral and maxillofacial pathology*. 3rd ed. West Philadelphia (PA): Saunders; 2009. p. 521-523.
3. Kendrick F, Waggoner W. Managing a peripheral ossifying fibroma. *ASDC J Dent Child* 1996 Mar-Apr;63(2):135-138.
4. Eversole LR, Rovin S. Reactive lesions of the gingival. *J Oral Pathol* 1972;1(1):30-38.
5. Miller CS, Henry RG, Damm DD. Proliferation mass found in the gingival. *J Am Dent Assoc* 1990 Oct;121(4):559-560.
6. Bhaskar SN, Jacoway JR. Peripheral fibroma and peripheral fibroma with calcification: report of 376 cases. *J Am Dent Assoc* 1966 Dec;73(6):1312-1320.
7. Gardner DG. The peripheral odontogenic fibroma: an attempt at clarification. *Oral Surg Oral Med Oral Pathol* 1982 Jul;54(1):40-48.
8. MacLeod RI, Soames JV. Epulides: a clinicopathological study of a series 200 consecutive lesions. *Br Dent J* 1987 Jul 25;163(2):51-53.
9. Kerr AR, Phelan JA. Benign lesions of the oral cavity. In: Greenberg MS, Glick M, Ship JA, editors. *Burket's oral medicine*. 11th ed. Hamilton: BC Decker Inc.; 2008. p. 133-134.
10. Poon CK, Kwan PC, Chao SY. Giant peripheral ossifying fibroma of the maxilla: report of a case. *J Oral Maxillofac Surg* 1995 Jun;53(6):695-698.
11. Wood NK, Goaz PW. Peripheral oral exophytic lesions. In: Wood NK, Goaz PW, editors. *Differential diagnosis of oral and maxillofacial lesions*. 5th ed. St Louis (MO): Mosby; 2006. p. 143-144.
12. Prasad S, Reddy SB, Patil SR, Kalburgi NB, Puranik RS. Peripheral ossifying fibroma and pyogenic granuloma. Are they interrelated? *N Y State Dent J* 2008 Mar;74(2):50-52.
13. Walters JD, Will JK, Hatfield RD, Cacchillo DA, Raabe DA. Excision and repair of the peripheral ossifying fibroma: a report of 3 cases. *J Periodontol* 2001 Jul;72(7):939-944.
14. Mesquita RA, Orsini SC, Sousa M, de Araújo NS. Proliferative activity in peripheral ossifying fibroma and ossifying fibroma. *J Oral Pathol Med* 1998 Feb;27(2):64-67.
15. Keluskar V, Byakodi R, Shah N. Peripheral ossifying fibroma. *J Indian Acad Oral Med Radiol* 2008;20(2):54-56.
16. Ono A, Tsukamoto G, Nagatsuka H, Yoshihama Y, Rivera RS, Katsurano M, Yao M, Sasaki A. An immunohistochemical evaluation of BMP-2, -4, osteopontin, osteocalcin and PCNA between ossifying fibromas of the jaws and peripheral cemento-ossifying fibromas on the gingiva. *Oral Oncol* 2007 Apr;43(4):339-344.
17. Lee KW. The fibrous epulis and related lesions. Granuloma pyogenicum, 'pregnancy tumor', fibro-epithelial polyp and calcifying fibroblastic granuloma. A clinicopathological study. *Periodontics* 1968 Dec;6(6):277-292.
18. Kumar SK, Ram S, Jorgensen MG, Shuler CF, Sedghizadeh PP. Multicentric peripheral ossifying fibroma. *J Oral Sci* 2006 Dec;48(4):239-243.
19. Feller L, Buskin A, Raubenheimer EJ. Cemento-ossifying fibroma: case report and review of the literature. *J Int Acad Periodontol* 2004 Oct;6(4):131-135.
20. Farquhar T, Maclellan J, Dymont H, Anderson RD. Peripheral ossifying fibroma: a case report. *J Can Dent Assoc* 2008 Nov;74(9):809-812.
21. Yadav R, Gulati A. Peripheral ossifying fibroma: a case report. *J Oral Sci* 2009 Mar;51(1):151-154.
22. Zain RB, Fei YJ. Fibrous lesions of the gingiva: a histopathologic analysis of 204 cases. *Oral Surg Oral Med Oral Pathol* 1990 Oct;70(4):466-470.
23. Eversole LR, Leider AS, Nelson K. Ossifying fibroma: a clinicopathologic study of sixty four cases. *Oral Surg Oral Med Oral Pathol* 1985 Nov;60(5):505-511.

24. Granizo RM, Cueallar AS, Falahat F. Cemento-ossifying fibroma of the upper gingivae. *Otolaryngol Head Neck Surg* 2000 May;122(5):775.
25. Marx RE, Stern D. Oral and maxillofacial pathology: a rationale for diagnosis and treatment. Chicago: Quintessence; 2003. p. 23-25.
26. Batsakis JG. Non-odontogenic tumors: clinical evaluation and pathology. In: Thawley SE, Panje WR, Batsakis JG, Lindberg RD, editors. *Comprehensive management of head and neck tumors*. 2nd ed. Philadelphia (PA): WBSaunders; 1999. p. 1641-1642.
27. Kenney JN, Kaugars GE, Abbey LM. Comparison between the peripheral ossifying fibroma and peripheral odontogenic fibroma. *J Oral Maxillofac Surg* 1989 Apr;47(4):378-382.
28. Buchner A, Hansen LS. The histomorphologic spectrum of peripheral ossifying fibroma. *Oral Surg Oral Med Oral Pathol* 1987 Apr;63(4):452-461.
29. Kumar SKS, et al. Multicentric peripheral ossifying fibroma: a case report. *J Oral Sci* 2009;51:151-154.
30. Flaitz CM. Peripheral ossifying fibroma of the maxillary gingival. *Am J Dent* 2001 Feb;14(1):56.
31. Das UM, Azher U. Peripheral ossifying fibroma. *J Indian Soc Pedod Prev Dent* 2009 Jan-Mar;27(1):49-51.